

Factors Influencing The Success Of Regenerative Endodontics In Immature Permanent Teeth

Siraj DAA Khan¹, Hassan Salem AAbu-Saq², Ahmad Mohammed A Almakrami²,
Mohammed Saeed MALabbas², Khalid Dhafer NAllyami², Salem Mohammed
NAlmasabi², Mahdi Mana M Al-Ghufaynah³

¹PhD, Pediatric Dentistry, Department of Preventive Dental Sciences, Faculty of Dentistry, Najran University, Saudi Arabia

²General Dental Practitioner, Faculty of Dentistry, Najran University, Saudi Arabia

³General Dental Practitioner, Faculty of Dentistry, Alexandria University, Egypt

ABSTRACT

Objective: This study explored the factors influencing the success of regenerative endodontic treatments (RETs) for immature permanent teeth. **Methodology:** a systematic search was conducted to search related articles in various databases such as PubMed, ScienceDirect, and Google Scholar. A total of 15 studies were selected. Different factors that affect the success of RET were extracted from the selected articles. **Results:** The findings of different studies indicated that various factors i.e. age of patients, tooth type, type of scaffold used, and duration of treatment can affect the success of RET. **Conclusion:** It can be concluded that various factors can influence the effectiveness of RET. However, further clinical trials are necessary to deepen our understanding.

Keywords: Regenerative endodontic treatment, immature, Factors, tooth type

INTRODUCTION

“Biologically based procedures which result in the replacement of damaged dentin and root structures, including other structures like cells of the pulp-dentin complex” are defined as regenerative endodontic procedures.¹ A big challenge for endodontists is the treatment of permanent immature teeth with apical pathosis and necrotic pulp. The Pulp in many of those teeth develops necrosis before the completion of root development. These conditions pose a challenge in the removal of necrotic pulp and filling and there is an increased risk of fracture due to thin dentinal walls.² Historically apexification was used to manage immature apices with open root ends.³ Resolution of infection and its associated symptoms were treated excellently with this technique but it did very little for continued development of

roots. Thus, apexification resulted in thin dentinal walls.⁴ In addition, clinicians may select the option of long-term use of calcium hydroxide in highly immature teeth to develop an apical calcific barrier. Long periods and multiple visits requiring compliance and long-term use of calcium hydroxide may result in several disadvantages including a change in the mechanical properties of dentin causing its fracture.⁵ So long-term prognosis is questionable even after the success of apexification because of the eventual root fracture resulting from thin dentinal walls.⁶ The use of an immediate apical plug has been advocated recently in which the apical portion of the canal is obliterated by the placement of an artificial apical plug. The excellent material used for this purpose is mineral trioxide aggregate (MTA).⁷ One of the goals of regenerative endodontics is to

promote continued root development and the removal of the disease process. Therefore, reinforcement of dentinal walls with the deposition of new dentin and continued lengthening of roots are achieved in regenerative endodontics. Regrowth of de novo tissues within the root canal space is described by the terms Revascularization, Regeneration, and Revitalization.⁸ There is progress in research work towards the successful regeneration of pulp-dentin complex (PDC) in which emphasis is given to the replacement of damaged structures like PDC cells, dentine, and root structures.⁹

It was recently reported in a study that the stage of root development plays a greater role in root fracture as compared to long-term use of calcium hydroxide $\text{Ca}(\text{OH})_2$.¹⁰ Patient's age, sex, type of tooth, preoperative periapical

lesion, etiology, duration of sign and symptoms, stage of root development, and follow-up period are factors that affect the success of treatment.¹¹ Regenerating pulpal tissues which allows for continued root formation provides an alternative approach for the treatment of immature necrotic permanent teeth. The main aim in this modality was the continued formation of the entire root rather than the formation of an apical calcific barrier which is known as apexification.¹² The existing studies on RET fail to encompass a comprehensive range of factors that influence its outcomes in successful cases. Hence, this systematic review endeavors to gather, analyze, and assess all documented successful instances of RET outlined in the available literature.

METHODOLOGY

Search strategy: An electronic search was conducted for English-language articles published between 2001 and 2022 using databases such as PubMed, ScienceDirect, and Google Scholar. The search employed specific keywords including immature teeth, immature tooth, pulp revascularization, pulpal regeneration, root canal revascularization, 'factors for successful regenerative endodontic,' 'regenerative endodontic therapy,' 'regenerative endodontic treatment,' 'platelet-rich fibrin,' 'platelet-rich plasma,' RET, Factors for RET, and Success of RET. The detailed search strategy is depicted in Figure 1.

Inclusion and Exclusion Criteria: The study will consider the inclusion of in vivo studies involving the practice of RET, published in English between 2001 and 2022, specifically those that documented at least one successful case of RET. Excluded from consideration are review articles, in vitro studies, editorials, theses, personal opinion articles, and studies

lacking reports of successful RET cases or involving non-human subjects.

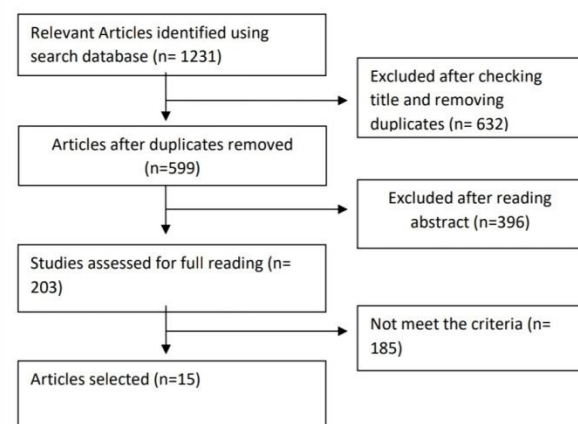


Fig. 1. search strategy for related articles

Data Extraction: Each reviewer independently assessed the titles and abstracts of the retrieved articles based on the specified eligibility criteria. Any discrepancies were resolved through discussion until a unanimous decision was reached. The initial selection of studies involved a review of their titles and abstracts. Subsequently, the complete texts of

the chosen articles were thoroughly examined. Data from the studies were collected and structured into a table containing the following details: author and publication year, study design, case count, patient age range, tooth type, treatment procedures employed (such as irrigation, intracanal medicaments, and the utilization of specific scaffolds), treatment duration, and factors influencing treatment outcome.

RESULTS

A total of 2,357 studies were acquired based on the specified keywords via database searches. Following a thorough review of titles and abstracts, 1,894 studies were excluded due to duplications or irrelevant content. Post application of inclusion and exclusion criteria, 185 articles underwent eligibility assessment. Eventually, 15 papers met the criteria and were chosen for inclusion in this review. The search strategy of this systematic review is illustrated in Figure 1. The search concluded with the incorporation of 15 human studies meeting both inclusion and exclusion criteria. These studies delved into various factors impacting the success of Resistance Exercise Training (RET) outcomes. The systematic review encompassed diverse study types: 7 case reports/case series,^{13-16,22,24,25} 2 prospective studies,^{17,20} 5 retrospective studies^{19,21,23,26,27} and 1 randomized clinical trial (RCT).¹⁸ Table 1 summarizes comprehensive details of the incorporated studies, elucidating the diverse factors impacting successful outcomes in RET.

In one instance¹³, the combination of a disinfected canal, a conducive matrix for tissue growth, and a secure coronal seal demonstrated an environment conducive to successful revascularization. Another approach detailed four clinical cases of immature teeth affected by periradicular periodontitis or abscess, undergoing conservative treatment without canal instrumentation. These cases provided

valuable insights, suggesting a favorable environment for tissue regeneration through a conservative approach.¹⁴ Additionally, a 7-year-old girl's maxillary left central incisor, diagnosed with necrotic pulp and acute apical periodontitis, underwent disinfection using 5% sodium hypochlorite. Induction of a blood clot into the root canal space was proposed as a potential method to promote revascularization in certain circumstances, advocating for a single visit revascularization procedure as a viable treatment option.¹⁶ In a prospective study conducted by Narang et al., patients were categorized into four groups for assessment. Group I served as the control, undergoing mineral trioxide aggregate apexification to evaluate the regenerative potential of blood clot and platelet concentrates. In Group II, the canal utilized a blood clot as a scaffold, while Group III incorporated Platelet-Rich Fibrin (PRF) as a scaffold. Group IV employed Platelet-Rich Plasma (PRP) carried on collagen as the scaffold. Statistical analysis indicated notably significant outcomes in Group III (PRF) compared to the other groups.¹⁷ Similarly, Bezgin et al.'s study demonstrated PRP's effectiveness in creating a scaffold for regenerative endodontic treatment. However, the treatment outcomes did not exhibit significant differences between PRP and the conventional blood clot scaffold.¹⁸ After treatment using specific irrigation and medications, 75% of 28 cases showed complete healing, 10.7% required further treatment, and 14% displayed incomplete healing.¹⁹ Revascularization procedures were viable for ages 9 to 18, with younger individuals showing better candidacy.²⁰ Analyzing 38 teeth treated with different methods revealed no statistical difference in outcomes at 1, 3, 6, and 12 months.²¹ After a regenerative endodontic procedure (REP), complications arose due to displaced mineral trioxide aggregate (MTA). Despite this, complete periapical healing, thickened

dentinal root walls, and full apex formation were observed three years post REP.²² In Peng et al. study, revascularization using MTA and GIC as canal-sealing materials showcased comparable survival rates (MTA: 96%, GIC: 100%). However, the success rate in the MTA group (93%) exceeded that in the GIC group (59%).²³ Another study highlighted the feasibility and success of using Ca(OH)_2 and MM-MTA in performing a regenerative endodontic procedure for managing an immature necrotic permanent molar.²⁴ Alasqah et al. conducted a study involving an immature necrotic mandibular molar that underwent a three-appointment Regenerative Endodontic Procedure (REP). The treatment included chemomechanical debridement, nonsetting calcium hydroxide application throughout the canal, triple antibiotic paste, and MTA placement over blood clots. Over two years of recall appointments, the tooth remained asymptomatic.²⁵ Jiang and Liu's study found a significant correlation between age, tooth type, and the achievement of primary and secondary goals ($p < 0.05$). Younger children at their initial visit age were more likely to reach these goals, while posterior teeth showed an advantage over anterior teeth in achieving these goals.²⁷

DISCUSSION

The endodontic treatment of immature permanent teeth with necrotic pulp, either with or without apical pathosis, presents numerous clinical complexities.² Recently, regenerative endodontics has emerged as a biologically rooted treatment alternative. In contrast to apexification procedures, regenerative approaches offer the potential for further root maturation in length and thickness by stimulating the regeneration of vital tissue.¹² Achieving thorough disinfection of the root canal, followed by the stimulation of residual stem cells, facilitates the ingrowth of newly formed pulplike tissue (known as the

revascularization procedure). This process can induce the generation of new hard tissue on the existing dentin wall, fostering continued root development.¹³ According to Lovelace et al.,²⁸ revascularization stands as a straightforward protocol that enhances pulp regeneration by utilizing a blood clot as a scaffold for autogenous stem cell release. However, the outcomes of revascularization procedures remain unpredictable and influenced by multiple factors. Patient age affects healing capacity, while the apical diameter may limit the influx of stem cells and blood vessels into newly formed tissue.¹² Limitations in the existing data encompass inadequate long-term follow-ups, small sample sizes, variations in clinical protocols, and diverse outcome measurements.²⁹ The attainment of the primary goal significantly impacted tooth survival, directly linked to the efficacy of root canal chemical disinfection. However, a challenge lies in safeguarding the tissue around the apical area while focusing on eliminating root canal bacteria. Some research indicates that current disinfection methods and drug concentrations might not entirely eradicate bacteria.³⁰ Another critical factor influencing the primary goal is the choice of root canal sealing material.²³ After treatment, most teeth showed varying degrees of root development, aligning with the achievement of the secondary goal. Some studies suggest that the hard tissue formed within the root canal post-REPs closely resembles bone- and cementum-like tissue.³¹ The tooth type significantly influenced achieving the secondary goal, favoring posterior teeth over anterior ones. An alternate study noted less predictable radiographical root development outcomes in treating immature permanent teeth with periradicular pathosis using REPs.³² Clinical findings indicated notably better outcomes in RET cases stemming from dens evaginatus compared to dental trauma.³³ To safeguard apical papilla stem cells, it's advised to use lower concentrations of intracanal

medicaments and irrigation solutions.³⁴ Multiple case reports and retrospective clinical studies have reported a high success rate for RET within follow-up periods ranging from 12 to 19 months.³³

Conclusion

In conclusion, Resistance Exercise Training (RET) emerges as a valuable approach within endodontics for addressing immature necrotic teeth in children and young adults, complementing existing treatment modalities. Current evidence suggests that RET exhibits high survival and success rates when treating immature teeth with pulp necrosis. Various factors such as patient age, tooth type, follow-up duration, and the type of scaffold utilized can influence the effectiveness of RET. However, further clinical trials are necessary to deepen our understanding.

REFERENCES

1. Murray PE, Garcia-Godoy F, Hargreaves KM. Regenerative endodontics: a review of current status and a call for action. *J Endod.* (2007) 33:377–90. doi: 10.1016/j.joen.2006.09.013.
2. Camp J, Fuks A. Pediatric endodontics: endodontic treatment for the primary and young permanent dentition. In: Cohen S, Hargreaves K, Keiser K, eds. *Pathways of the Pulp*, 9th ed. St Louis, MO: Mosby Elsevier; 2006:822–82.
3. Cvek M, Sundstrom B. Treatment of non-vital permanent incisors with calcium hydroxide: V—histologic appearance of roentgenographically demonstrable apical closure of immature roots. *Odontol Revy* 1974;25:379–91.
4. Bose R, Nummikoski P, Hargreaves K. A retrospective evaluation of radiographic outcomes in immature teeth with necrotic root canal systems treated with regenerative endodontic procedures. *J Endod* 2009;35:1343–9.
5. Yassen GH, Platt JA. The effect of nonsetting calcium hydroxide on root fracture and mechanical properties of radicular dentine: a systematic review. *Int Endod J* 2013; 46:112–8.
6. Andreasen J, Farik B, Munksgaard E. Long term calcium hydroxide as a root canal dressing may increase risk of root fracture. *Dent Traumatol* 2002;18:134–7.
7. Holden DT, Schwartz SA, Kirkpatrick TC, Schindler WG. Clinical outcomes of artificial root end barriers with mineral trioxide aggregate in teeth with immature apices. *J Endod* 2008;34:812–7.
8. Diogenes A, Henry MA, Teixeira FB, Hargreaves KM. An update on clinical regenerative endodontics. *Endod Topics* 2013;28:2–23.
9. Kim SG, Zhou J, Solomon C, Zheng Y, Suzuki T, Chen M, et al. Effects of growth factors on dental stem/progenitor cells. *Dent Clin North Am.* 2012; 56:563–75.
10. Kahler SL, Shetty S, Andreasen FM, Kahler B. The effect of longterm dressing with calcium hydroxide on the fracture susceptibility of teeth. *J Endod.* 2018; 44:464–9.
11. Nolla CM. The development of the permanent teeth. *J Dent Child.* 1960;27:254–66.
12. Hargreaves K, Law A. Regenerative endodontics. In: Hargreaves K, Cohen S, eds. *Pathways of the Pulp*, 10th ed. St Louis, MO: Mosby Elsevier; 2011:602–19.
13. Banchs F, Trope M. Revascularization of immature permanent teeth with apical periodontitis: new treatment protocol? *J Endod.* 2004; 30:196–200.
14. Chueh LH, Huang GT. Immature teeth with periradicular periodontitis or abscess undergoing apexogenesis: a paradigm shift. *J Endod.* 2006; 32:1205–13.

15. Thibodeau, B.; Trope, M. Pulp Revascularization of A Necrotic Infected Immature Permanent Tooth: Case Report And Review Of The Literature. *Pediatr. Dent.* 2007, 29, 47–50.
16. McCabe P. Revascularization of an immature tooth with apical periodontitis using a single visit protocol: A case report. *Int Endod J.* 2015;48(5):484–497. doi:10.1111/iej.12344.
17. Narang I, Mittal N, Mishra N. A comparative evaluation of the blood clot, platelet-rich plasma, and platelet-rich fibrin in regeneration of necrotic immature permanent teeth: A clinical study. *Contemp Clin Dent.* 2015;6(1):63–68. doi:10.4103/0976-237X.149294.
18. Bezgin T, Yilmaz AD, Celik BN, Kolsuz ME, Sonmez H. Efficacy of platelet-rich plasma as a scaffold in regenerative endodontic treatment. *J Endod.* 2015;41(1):36–44. doi:10.1016/j.joen.2014.10.004.
19. Bukhari S, Kohli MR, Setzer F, Karabucak B. Outcome of revascularization procedure: A retrospective case series. *J Endod.* 2016;42(12):1752–1759. doi:10.1016/j.joen.2016.06.021.
20. Estefan BS, El Batouty KM, Nagy MM, Diogenes A. Influence of age and apical diameter on the success of endodontic regeneration procedures. *J Endod.* 2016; 42(11): 1620-1625. doi:10.1016/j.joen.2016.06.020
21. Chen SJ, Chen LP. Radiographic outcome of necrotic immature teeth treated with two endodontic techniques: A retrospective analysis. *Biomed J.* 2016; 39(5): 366-371. doi:10.1016/j.bj.2015.12.006
22. Timmerman A, Parashos P. Delayed root development by displaced mineral trioxide aggregate after regenerative endodontics: A case report. *J Endod.* 2017; 43(2): 252-256. doi:10.1016/j.joen.2016.10.024.
23. Peng C, Yang Y, Zhao Y, et al. Long-term treatment outcomes in immature permanent teeth by revascularisation using MTA and GIC as canal-sealing materials: A retrospective study. *Int J Paediatr Dent.* 2017;27(6):454–462. doi:10.1111/ipd.12282.
24. Ajram J, Khalil I, Gergi R, Zogheib C. Management of an immature necrotic permanent molar with apical periodontitis treated by regenerative endodontic protocol using calcium hydroxide and MM-MTA: A case report with two years follow up. *Dent J (Basel).* 2019; 7(1): 1. doi:10.3390/dj7010001.
25. Alasqah M, Raja Khan SI, Alfouzan K, Jamleh A. Regenerative endodontic management of an immature molar using calcium hydroxide and triple antibiotic paste: A two-year follow-up. *Case Rep Dent.* 2020;2020:9025847. doi:10.1155/2020/9025847.
26. Vanessa Chrepa, Ruchika Joon, Obadah Austah, Anibal Diogenes, Kenneth M. Hargreaves, Mostafa Ezeldeen, and Nikita B. Ruparel. Clinical Outcomes of Immature Teeth Treated with Regenerative Endodontic Procedures—A San Antonio Study. *Endod* 2020; 1–11.
27. Xijun Jiang and He Liu. Analysis of the achievement of primary and secondary goals and influencing factors in single-rooted immature permanent teeth after regenerative endodontic procedures: a retrospective study. *BMC Oral Health* (2023) 23:851.
28. Lovelace TW, Henry MA, Hargreaves KM, Diogenes A. Evaluation of the delivery of mesenchymal stem cells into the root canal space of necrotic immature teeth after clinical regenerative endodontic procedure. *J Endod* 2011;35:1343–9.
29. Torabinejad M, Nosrat A, Verma P, Udochukwu O. Regenerative endodontic

- treatment or mineral trioxide aggregate apical plug in teeth with necrotic pulps and open apices: a systematic review and meta-analysis. *J Endod* 2017;43:1806–20.
30. Martin DE, et al. Concentration-dependent effect of sodium hypochlorite on stem cells of apical papilla survival and differentiation. *J Endod*. 2014;40(1):51–5.
 31. Andreasen JO, Bakland LK. Pulp regeneration after non-infected and infected necrosis, what type of tissue do we want? A review. *Dent Traumatol*. 2012;28(1):13–8.
 32. Shetty H, Shetty S, Kakade A, Mali S, Shetty A, Neelakantan P. Three-dimensional qualitative and quantitative analyses of the effect of periradicular lesions on the outcome of regenerative endodontic procedures: a prospective clinical study. *Clin Oral Investig*. 2021;25(2):691–700.
 33. Lin J, Zeng Q, Wei X, et al. Regenerative endodontics versus apexification in immature permanent teeth with apical periodontitis: A prospective randomized controlled study. *J Endod*. 2017;43(11):1821–1827. doi:10.1016/j.joen.2017.06.023.
 34. American Association of Endodontists. AAE clinical considerations for a regenerative procedure. Revised 4/1/2018. https://www.aae.org/specialty/wp-content/uploads/sites/2/2018/06/Considerations-ForRegEndo_AsOfApril2018.pdf. Accessed September 23, 2018.

Table: 1. Different factors influencing Regenerative endodontics treatment RET outcome

| Author | Study type | Number of patients | Age | Tooth type | Intra-canal medication/irrigation | Capping material/ Restoration | Scaffold | Duration | Outcomes |
|--------------------------------|-------------------|-------------------------|------------|-----------------------------|-----------------------------------|-------------------------------|--|------------------|---|
| Banchs and Trope, 2004 (13) | Case report | 1 | 11 Years | Lower right second premolar | 5.25% NaOCl/Triple antibiotics | MTA | Blood clot | 2 years | Based on positive outcome, it can be assumed that this combination successfully sealed the tooth from coronal bacterial leakage |
| Chueh and Huang, 2006 (14) | case report | 4 2 male 2 female | 9-10 years | mandibular posterior | 2.5% NaOCl/Calcium hydroxide | Amalgam | None | 7 months-5 years | successful regenerative endodontic was found with the conservative method |
| Thibodeau and Trope, 2007 (15) | Case report | 1 | | maxillary central incisor | antibiotic paste | MTA | blood clot | 1 year | successful regenerative endodontic was found |
| McCabe et al, 2015 (16) | Case report | 1 | 7 years | Anterior tooth | 5% NaOCl and 17% EDTA | MTA | Blood clot | 1.5 years | Induction of blood clot after irrigation with 5% NaOCl resulted in sufficient revascularization |
| Narang et al., 2015 (17) | Prospective study | 15 | Below 20 | NA | Triple antibiotic/2.5% NaOCl | GIC | Group I= Blood clot Group II= PRP Group III= PRF | 1.5 years | PRF showed huge potential to accelerate the growth characteristics as compared to the PRP and blood clot |

| | | | | | | | | | |
|-----------------------------------|---------------------|-----------------------------|---------------|--|---|------------------------------|------------------------|--------------------------------|---|
| Bezgin et al., 2015 (18) | RCT | 19 Male =10 Female =9 | 10.1 ±1.85 | Anterior =13 Posterior =6 | Antibiotic/2.5% NaOCl, 17% EDTA and 0.12% CHX | MTA | Blood clot=9 PRP=10 | 1.5 years | In PRP group, mean time for apical closure was 8.1 months while in Blood Clot group it was 9 months |
| Bukhari et al., 2016 (19) | Retrospective study | 28 | 8-31 years | Anterior =19 Posterior =6 | Antibiotic/3% NaOCl and 17% EDTA | Bioceramic putty or MTA | Blood clot | 2 years (12) 4-6 years (13) | 21 patients (75%) healed completely, 3 patients needed further treatment, 4 cases presented incomplete healing |
| Estefan et al., 2016 (20) | Prospective study | 40 | 9 to 18 years | Anterior Teeth (Maxillary incisors) | Antibiotic/2.5% NaOCl and 17% EDTA | MTA | Blood clot | 1 year | Revascularization was better in younger age group (9 to 13 years) than the older ones (14 to 18 years) |
| Chen and Chen, 2016 (21) | Retrospective study | 16 | 10.90 ±0.98 | posterior teeth (premolars) | Ca(OH) ₂ /2.5% NaOCl | MTA | Blood clot | 1 years | There was no statistical difference between the two treatments regarding PAI scores at the 1-, 3-, 6-, and 12-month follow-up (p > 0.05). |
| Timmerman and Parashos, 2017 (22) | Case report | 1 | 16 years | anterior tooth (maxillary lateral incisor) | Ca(OH) ₂ /1% NaOCl and 15% EDTA | MTA | Blood clot | 3 years | REP can potentially provide excellent treatment outcomes for structurally compromised teeth |
| Peng et al., 2017 (23) | retrospective study | 45 | 10.8 ±1.92 | ----- | Antibiotic/5.25% NaOCl | Group 1= GIC Group 2= MTA | Blood clot | 2.5-3 years | Long-term outcome of revascularisation in non-vital immature permanent teeth sealed |

| | | | | | | | | | |
|---------------------------|---------------|------------------------------|------------|--|---|----------|---|--------------|---|
| | | | | | | | | | with GIC was not as good as that with MTA. |
| Arjam et al., 2019 (24) | Case report | 1 | 7 years | posterior tooth (mandibular first molar) | Ca(OH) ₂ /10 mL sterile saline and 20% EDTA | MTA | Blood clot | 2 years | CBCT at two years follow-up confirmed apical closure and complete healing. |
| Alasqah et al., 2020 (25) | Case report | 1 | 8 years | posterior tooth (mandibular first molar) | antibiotic and Ca(OH) ₂ /1.5% NaOCl and 17% EDTA | MTA | Blood clot | 2 years | complete root formation with significant periapical healing was evident radiographically after 2 years of recall appointments |
| Chrepa et al., 2020 (26) | retrospective | 51 | 7-26 years | --- | chlorhexidine after NaOCl/Ca(OH) ₂ , calcium hydroxide; DAP, double antibiotic paste | Multiple | | 1-8.2 years | age was significantly associated with success with higher age being associated with a decreased success rate (P , .001) |
| Jiang and Liu, 2023 (27) | Retrospective | 408 (212 males, 196 females) | 6–16 years | anterior and posterior teeth | Calcium hydroxide paste or antibiotic paste /1.5-3% NaOCl | MTA, GIC | blood clots, platelet-rich fibrin, and collagen membranes | 4–107 months | The achievement of the primary and secondary goals were significantly related to age and tooth type (p < 0.05). |