

Mucoid Degeneration of the Posterior Cruciate Ligament: A Case Report of a Rare Condition.

¹Dr. Sagar Gurnani

Senior Resident, Department of Orthopaedics,
Dr. D.Y. Patil Medical College, Hospital and Research Centre,
Dr. D.Y. Patil Vidyapeeth, Pimpri, Pune.

Email: sagar658@gmail.com

²Dr. Rajeev Reddy

Junior Resident, Department of Orthopaedics,
Dr. D.Y. Patil Medical College, Hospital and Research Centre,
Dr. D.Y. Patil Vidyapeeth, Pimpri, Pune.

Email: rajeevreddy468@gmail.com

Corresponding Author: **Dr. Tushar Chaudhari**

Assistant professor, Department of Orthopaedics,
Dr. D.Y. Patil Medical College, Hospital and Research Centre,
Dr. D.Y. Patil Vidyapeeth, Pimpri, Pune.

Email: orthotushar@gmail.com

ABSTRACT

Mucoid degeneration of the cruciate ligament can occasionally result in knee pain and restriction in range of motion. A 45-year-old female presented to the outpatient department complaining of pain in her right knee joint when she extended it to its fullest extent. The range of motion (ROM) was 10 degrees of flexion contracture, with forced extension exacerbating the pain. Posterior cruciate ligament (PCL) mucoid degeneration was detected in the knee on magnetic resonance imaging. The procedure of arthroscopic treatment involves PCL reduction, which lowers the volume of the hypertrophied PCL by debridement of yellowish material in the PCL fibres. After surgery, the patient regains full range of motion without experiencing any impingement symptoms. Enlarged PCL can lead to an impingement in the femoral notch with the anterior cruciate ligament (ACL). According to previously published literature on PCL mucoid

degeneration, pain is more felt in the posterior aspect of the knee, which aggravates as the knee achieves full flexion. Therefore, the clinician should maintain a high degree of suspicion and requires thorough clinical assessment, imaging, and investigations to rule out the exact diagnosis. Then, partial debulking surgery of PCL is an effective treatment for pain relief and restoring the full range of motion in the knee. Here, we describe a case of posterior cruciate ligament mucoid degeneration presented with secondary ACL impingement syndrome treated with arthroscopic debridement.

Introduction

Anterior cruciate ligament (ACL) mucoid degeneration is a benign knee pathology that occurs in 1.8% to 5.3% [1-2]. Although mucoid degeneration of the ACL is well reported, not much is known about this clinical entity. Kumar et al. originally reported this ACL lesion in 1999 [3]. According to their report, a biopsy revealed mucoid degeneration and arthroscopic partial resection of the ligament could potentially alleviate symptoms. ACL mucoid degeneration is classified as a degenerative disease; not all lesions are symptomatic, and it is distinguished from cyst-like lesions by a mucoid substance infiltrating the ligament [4]. While ACL mucoid degeneration is more common and has been documented in numerous cases in the literature, the posterior cruciate ligament (PCL) has only been documented in a small number of cases. However, there are some circumstances that cause knee pain. We believe that the patient's symptoms are due to hypertrophic PCL with mucoid degeneration causing roof impingement with ACL, based on the physical examination, the

patient's history, and the pain characteristics [5]. Here, we report a case of PCL mucoid degeneration that manifested as ACL impingement symptoms.

Case Presentation

A 45-year-old woman presented to the out-patient department with complaints of pain in her right knee since six months, more during terminal extension of knee. Pain worsened with increase in activity, but there was no history of previous fall or trauma. She had no other comorbidities. Upon physical examination, a joint effusion was noted with a restricted range of motion. There was a 10-degree flexion deformity and a 135-degree flexion range of motion. No tenderness was elicited on the medial joint line. Anterior drawer, posterior drawer, and pivot shift test findings showed no signs of knee instability or posterior sagging. X-ray of right knee was done which revealed reduction in the medial joint space (Figure 1).

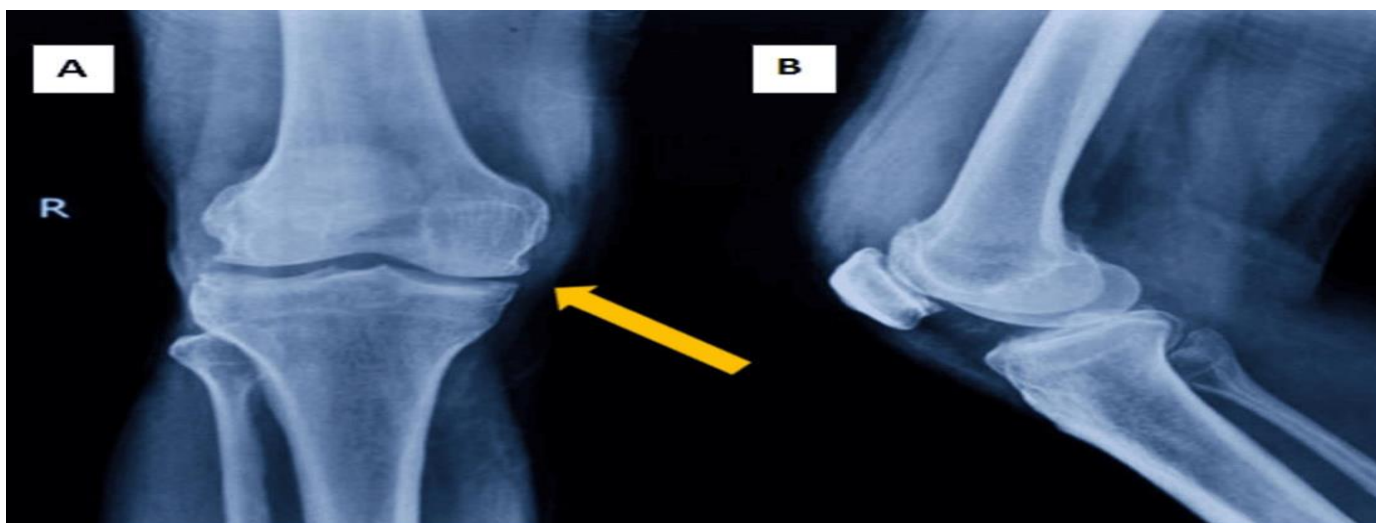


FIGURE 1: Xray of the right knee anteroposterior (AP) and lateral view
Arrow on the AP view shows medial joint space narrowing in the right knee

A thicker posterior cruciate ligament (PCL) with enhanced intra-ligamentous signal intensity was seen on magnetic resonance imaging (MRI) of the knee. (Figure 2).

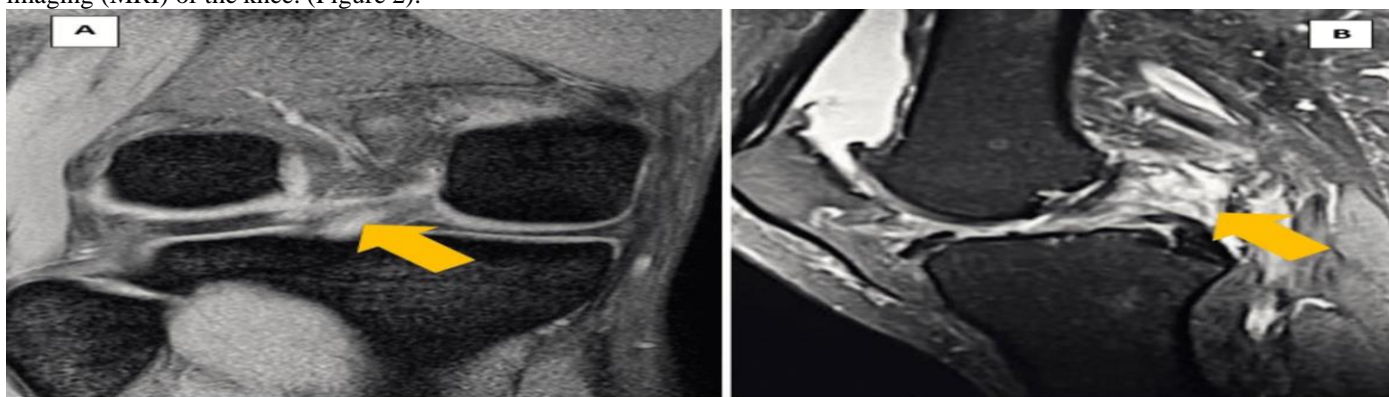


FIGURE 2: Coronal and Sagittal T2-weighted images of the lesion in the posterior cruciate ligament (PCL).

2A: Coronal T2-weighted images of the PCL showing enhanced signal intensity area within the PCL.

2B: Sagittal T2-weighted images of the PCL showing enhanced signal intensity area within the PCL.

Upon arthroscopic evaluation, the PCL was found to be significantly thicker, filled with a yellowish hue in the ligament (Figure 3).

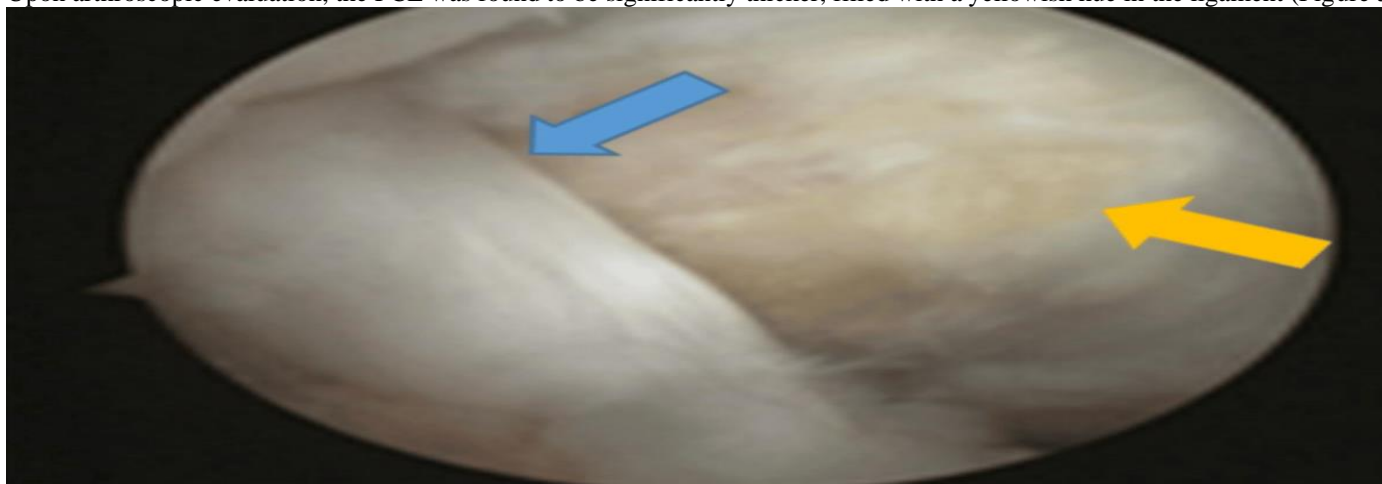

FIGURE 3: Arthroscopic image showing normal anterior cruciate ligament and thickened PCL.

Blue arrow shows a normal anterior cruciate ligament.

Orange arrow shows PCL showing degenerated PCL with mucoid hue.

The anterior cruciate ligament appeared and felt normal when probed, but it was pressed in the direction of the notch's lateral wall, impinging on both the wall's flexion and the roof's extension. The PCL fibres own tension was normal upon probing, indicating the lack of a PCL tear. Debridement of PCL was done along with notchplasty on the roof and lateral walls and then rechecked for impingement. Lachmann and Pivot shift results following the arthroscopic operation were negative, ruling out instability. The lateral meniscus and the medial meniscus appeared normal.

Rehabilitation with early physiotherapy began on the second surgical day. The patient experienced no pain following surgery and regained a complete range of motion. At the patient's one-year follow-up, there were no symptoms.

Discussion

Since PCL mucoïd degeneration is usually asymptomatic and incidentally observed, it is challenging to determine the true incidence of this condition. For comparison, Bergin et al. reported that the incidence of PCL mucoïd degeneration in reference was 0.1% (14/12972), whereas the incidence of ACL mucoïd degeneration is 1.0% (44/4221) [6]. A small number of case reports and previous descriptions of mucoïd degeneration of PCL describe patients who either have no symptoms at all or have PCL symptoms such as pain during flexion [7]. Mucoïd degeneration of PCL resembles the appearance of a tram track [8], and in our case, the femoral notch was filled with hypertrophic PCL and ACL, leading ultimately to an ACL impingement-like symptom. PCL showed a yellowish hue, which was characteristic for mucoïd degeneration. The yellow color was not liquid but rather fibrous tissue, according to reports on ACL mucoïd degeneration [9]. Preventing posterior instability required careful debulking of PCL through the yellowish substance. Pain was relieved right away, and range of motion was enhanced, with partial debulking of the PCL. The tissue's histological analysis indicated posterior cruciate ligament mucoïd degeneration [10]. This was the recommended modality in our case because arthroscopic debulking of the PCL has a shorter recovery period. Rapid recovery is guaranteed, and arthroscopic procedures result in less tissue damage, blood loss, and scarring.

Conclusions

Even though mucoïd degeneration is usually asymptomatic, it can occasionally cause discomfort and deformity. ACL impingement symptoms could result from a big posterior cruciate ligament that pushes the ACL into the notch. According to previously published literature, PCL mucoïd degeneration presents as

posterior knee pain and pain in terminal stages of flexion. Therefore, any patient with chronic refractory knee pain deserves a thorough clinical assessment and imaging to rule out the exact cause. Effective therapeutic options with quick postoperative pain relief and acceptable functional outcomes include partial debulking of the PCL and notchplasty. We conclude that arthroscopic decompression of the PCL offers less morbidity as compared to the open method and, at the same time, will relieve knee pain and facilitate an early return to normal with good functional results.

References

1. Wang J.H. , Jangir R.R. : Mucoïd Degeneration of Posterior Cruciate Ligament with Secondary Impingement of Anterior Cruciate Ligament: A Rare Case Report. *Journal of Orthopaedic Case Reports*. 2015, 5:44-46. 10.13107/jocr.2250-0685.343
2. Morice, A., Couprie, A.: Reduction Plasty for Hypertrophic Anterior Cruciate Ligament Mucoïd Degeneration: Clinical and Knee Laxity Outcomes in 23 Cases. *Orthopaedics & Traumatology: Surgery & Research*. 2013, 99:693-697. 10.1016/j.otsr.2013.04.010
3. Kumar, A., Bickerstaff, D.R.: Mucoïd Cystic Degeneration of the Cruciate Ligament. *Journal of Bone and Joint Surgery*. 1999, 81:304-305. 10.1302/0301-620X.81B2.0810304
4. Parkar, A.P., Vanhoenacker, F.M. : Bilateral Mucoïd Degeneration of the Posterior Cruciate Ligaments . 2007, 96:298-300. 10.5334/jbr-btr.418
5. Matsumoto, A.; Howell, S.M. : Avoiding Posterior Cruciate Ligament and Roof Impingement with Transtibial Anterior Cruciate Ligament Reconstruction: Keys to Correct Tunnel Placement. 2005, 20:211-217. 10.1097/01.bto.0000177270.61591.f4
6. Bergin, D., Morrison, W.B. : Anterior Cruciate Ligament Ganglia and Mucoïd Degeneration: Coexistence and Clinical Correlation. *American Journal of Roentgenology*, 182, 1283-1287. 2004. 10.2214/ajr.182.5.1821283
7. Okazaki, K., Deguchi, S.: Mucoïd Degeneration of the Posterior Cruciate Ligament: A Case Report . *Knee Surgery, Sports Traumatology, Arthroscopy*. 2001, 19:105-107. 10.1007/s00167-010-1171-8
8. McMonagle, J.S., Helms, C.A.: Tram-Track Appearance of the Posterior Cruciate Ligament (PCL): Correlations with Mucoïd Degeneration, Ligamentous Stability, and Differentiation from PCL Tears. *American Journal*. 2013, 201:394-399. 10.2214/AJR.11.7400
9. Cha, J.R., Lee, C.C. : Symptomatic Mucoïd Degeneration of the Anterior Cruciate Ligament. *Knee Surgery, Sports Traumatology, Arthroscopy*. 2013, 21:658-663. 10.1007/s00167-012-1991-9
10. Kumar, A., Bickerstaff, D.R.: Mucoïd Cystic Degeneration of the Cruciate Ligament. *The Journal of Bone and Joint Surgery*. 1999, 81:304-305. 10.1302/0301-620x.81b2.0810304